

Research Journal of Pharmaceutical, Biological and Chemical Sciences

Associated Impacts The Participant with Two Kinds of Worms (Cestoda) *Raillietinacesticillus* and (Nematodes) *Ascaridiagalli* in Domestic Chickens

Sukayna Jabbar Mushattat*.

Karbala University, College of Nursing, Iraq.

ABSTRACT

Twenty domestic chickens infected with two types of severe Cestoda and Nematoda examined in the veterinary hospital in Najaf province / Iraq for the period from the March until July 2016. Haematological and serum biochemical parameters were measured in the samples collected. Variations in the levels of these parameters were determined. The parameters measured showed significant lowest variations in infected chickens compare with non-infected chickens. These include RBC, PCV, Hb, MVC, MCH, MCHC, Na⁺, K⁺, Ca, CL, ALP, GPT, GOTM and Creatinine. The parameters measured of WBC showed highest significant variations in infected chickens compare with non-infected chickens. The pathological changes represented a clear macroscopic swelling and swelling of the duodenum, while histological changes was very clear and is represented by the occurrence of inflammation of the epithelial layer is accompanied by a massive infiltration of cells. Inflammatory injury and epithelial disjointed cells. Occurrence of macular show caused by the presence Parasite in the intestine leads to the disintegration of the villi where the exits, look devoid of the original features of any erosion of epithelial cells lining the intestinal villi and glands

Keywords: MCH, infection, economic.

*Corresponding author

INTRODUCTION

Parasitism is one of the main problems that cause economic losses in domestic poultry, including growth retardation and weight loss, diarrhea and bowel obstruction and increase the rate of injuries^[6]. Poultry exposed to nit internal and external parasites and worms are the most important internal worms are Cestoda (tapeworms) and Nematoda.^[7] Characterized tapeworms as worms long flat compressed top and bottom, and these worms *Raillietinacesticillus* worm that lives in small intestines, causing several changes for the host, including general weakness and severe diarrhea and wasting and because of the diversity of chicken feed grain and worm the Land and insects in the clay material^[5], so the chickens at risk of those phases misfortune of some parasitic worms and thus the growth of adult worms)^[4]. Nematodes or roundworms are the most important group of helminth parasites of poultry. This is due to the large number of parasitic species that cause damage to the host, especially in severe infections. Roundworms are elongated, cylindrical and unsegmented^[2]. They are covered with a tough, noncellular layer called the cuticle. Roundworms have a well-developed alimentary tract^[7]. *Ascaridiagalli* is a parasitic roundworm belonging to the phylum Nematoda. the genus *Ascaridia* are essentially intestinal parasites of birds.^[10] *A. galli* is the most prevalent and pathogenic species, especially in domestic fowl^[1]. It causes ascariasis, a disease of poultry due to heavy worm infection, particularly in chicken and turkeys. It inhabits the small intestine, and can be occasionally seen in commercial eggs. Effects: Weight depression. In severe infections, intestinal blockage can occur. At high levels of infection, there is loss of blood, reduced blood sugar content, retarded growth and greatly increased mortality. Parasite can occasionally be seen in commercial eggs^[10].

MATERIALS AND METHODS

Were examined 80 from the local chicken, which was suffering from satisfactory injuries in the veterinary hospital for the period from March until July, and by laboratory testing of stool indicate the presence of 20 cases suffer from injury with two types of worms (tapeworms and nematodes).

About 2 ml of blood was collected through the jugular vein from each bird, 0.5 ml of which was dispensed into clean bijoux bottles containing anticoagulant EDTA. The rest was allowed to clot^[18]. The anticoagulated blood was used to determine red blood cell (RBC) count, packed cell volume (PCV), haemoglobin (Hb) concentration, and white blood cell (WBC) count. Serum was separated from the clotted blood following centrifugation at 3,000 r.p.m. for 10 minutes at room (28 C), and stored at - 20 C until required for other tests^[12].

Experimental procedure: Red and white blood cells were counted using the haemocytometer method, PCV by the microhaematocrit method, and Hb concentration by the cyanmethaemoglobin method. Mean corpuscular volume (MCV), MCH, and MCHC were calculated from the above as described by^[12]. Serum sodium, potassium and calcium were determined with a flame photometer^[17]. Serum enzymes glutamate pyruvate transaminase (GPT) and glutamate oxalate transaminase (GOT) were converted to oxoacids and then coupled to 2, 4, dinitrophenyl-hydrazine forming hydrazone, the intensity of the colour of which depends on the quantity of enzyme present^[13]. The enzyme alkaline phosphatase and ALP were measured by a reaction which terminated in colour development measured at 500 nm wavelength^[3]. creatinine were determined using the standard Technicon methods of the analyser^[18].

Histological study: The pieces of small intestine were taken. These tissues were fixed in the "Bouins fluid" for 24 hours, dehydrated in the series of ascending grade of alcohol (70%, 80%, 90%, 95%, 100%), cleared in xylene, infiltrated in paraffin, embedded in paraffin and the paraffin blocks were sectioned at 6 µm thickness using sliding microtome^[19]. The sections were floated on luke-warm water in a floatation bath for stretching and then the paraffin sections were mounted on slides using an egg albumin and dried on slide warmer. The sections were then stained with standard Haematoxylin and Eosin method for general microscopic study^[19]

statistical analysis: analysis was conducted using the method Least Significant Difference L.S.D. of the experiment and the level of probability $P < 0.05$ to find a moral differences between the rates of measurements used in this experiment. analysis were performed according to (22).

RESULTS

Red blood cell count, PCV and Hb concentration all varied in a similar pattern. As shown in table 1, mean value of RBC is significantly ($P<0.05$) 2.22 ± 0.2 ($10^6/\mu\text{l}$) less than non-infected chicken it was 4 ± 0.1 ($10^6/\mu\text{l}$). The mean value of PCV in infected was $26.4 \pm 2.80\%$. This is significantly ($P<0.05$) less than the value of Non-infected it was $35 \pm 2.90\%$. The Hb concentration of $8.4 \pm 0.22 \text{ mg/dl}$ is significantly ($P<0.05$) less than Non-infected it was $11 \pm 0.31 \text{ mg/dl}$. Mean values of MCV ($116.9 \pm 3.45 \mu\text{m}^3$), MCH ($37.8 \pm 2.2 \text{ pg}$) and MCHC ($31.8 \pm 1.8 \text{ g/dl}$) were lowest in infected and highest in non-infected significantly ($P<0.05$). White blood cells peak value in infected chickens 116.3 ± 2.93 ($10^3/\mu\text{l}$) higher than the value of non-infected it was 100.1 ± 2.82 ($10^3/\mu\text{l}$). A significant ($P<0.05$). Serum Na^+ , K^+ , Ca^{++} and Cl^- ion concentrations also varied significantly ($P<0.05$). The serum electrolytes are significantly lowest than the value of non-infected chicken (Table 2). Among the enzymes measured, GOT is significantly lowest $31.0 \pm 2.5 \text{ IU/L}$ than non-infected it was $35 \pm 1.9 \text{ IU/L}$. ALP is significantly ($P<0.05$) higher than the value of infected chicken $164.8 \pm 23 \text{ IU/L}$. The value of GPT is significantly ($P<0.05$) lower in infected chicken $22.1 \pm 1.7 \text{ IU/L}$ than non-infected it was $25 \pm 1.8 \text{ IU/L}$. The concentration of Creatinine enzyme was $0.91 \pm 0.20 \text{ IU/L}$ compare with non-infected it $1.2 \pm 0.6 \text{ IU/L}$. A significant ($P<0.05$) (Table 3).

Table 1: some haematological parameters in the Infected Non-infected and local chickens

Parameters	Infected	Non-infected	L.S.D
PCV (%0)	26.4 ± 2.80	35 ± 2.90	2.432
Hb (g/dl)	8.4 ± 0.22	11 ± 0.31	1.561
RBC ($10^6/\mu\text{l}$)	2.22 ± 0.2	4 ± 0.1	1.233
WBC ($10^3/\mu\text{l}$)	116.3 ± 2.93	100.1 ± 2.82	2.452
MCV (μm^3)	116.9 ± 3.45	80 ± 2.6	2.336
MCH (pg)	37.8 ± 2.2	26 ± 1.2	1.248
MCHC (g/dl)	31.8 ± 1.8	31 ± 1.5	0.900

Table 2: Serumelectrolytes in the Infected Non-infected and local chickens

Parameters	Infected	Non-infected	L.S.D
Na (mm/l)	125 ± 4.2	130 ± 2.9	2.641
K (mm/l)	5.6 ± 0.7	6.0 ± 0.5	0.201
Ca (mm/l)	2.0 ± 0.9	0.8 ± 0.6	0.321
CL (mm/l)	99 ± 3.0	108 ± 3.2	2.120

Table 3: Serum biochemical parameters in the Infected Non-infected and chickens

Parameters	Infected	Non-infected	L.S.D
GPT (IU/L)	22.1 ± 1.7	25 ± 1.8	1.899
GOT (IU/L)	31.0 ± 2.5	35 ± 1.9	1.965
ALP (IU/L)	164.8 ± 23	180 ± 2.7	2.651
Creatinine (mg/dl)	0.91 ± 0.20	1.2 ± 0.6	0.231



Image (1): the parasites *Raillietinacesticillus* and *Ascaridiagalli* that isolation from digestive tract in domestic chickens

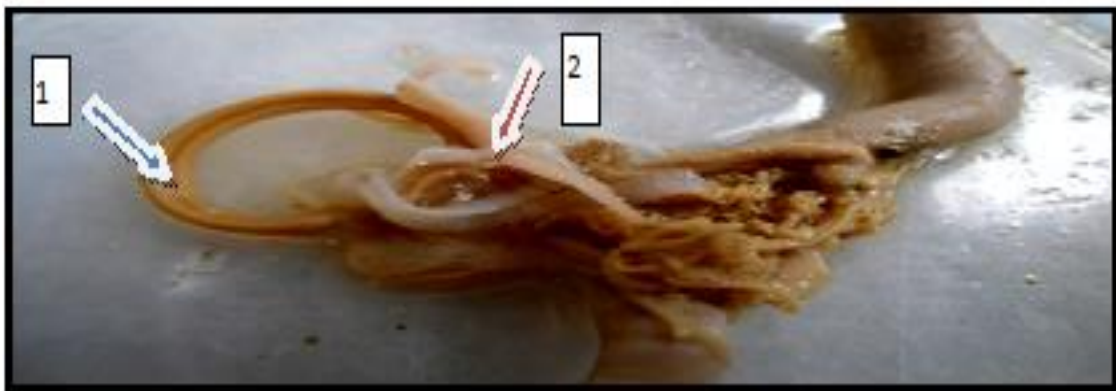


Image (2): The digestive tract showing the heavy infestation with *Raillietinacesticillus* (2) and *Ascaridiagalli* (1) in domestic chickens

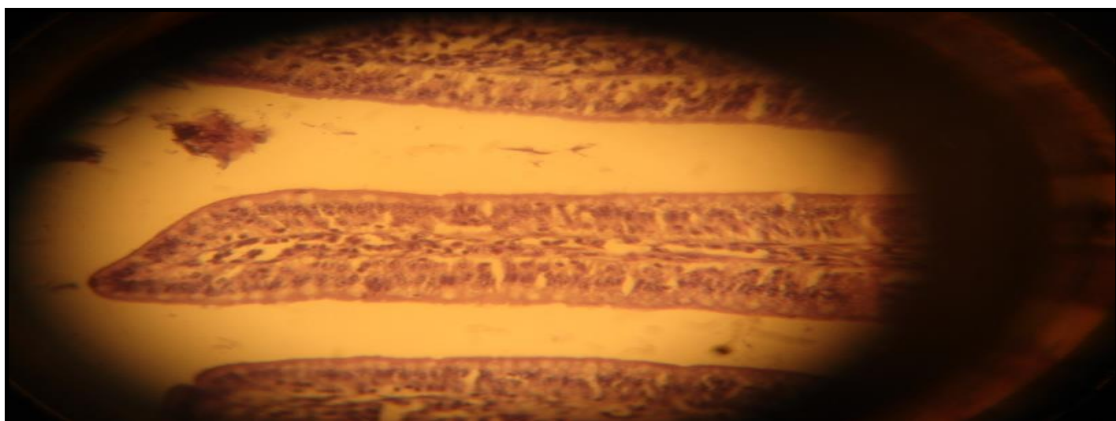


Image (3): the image of the digestive tract of chickens describes the installation of villus in control transactions 40x.

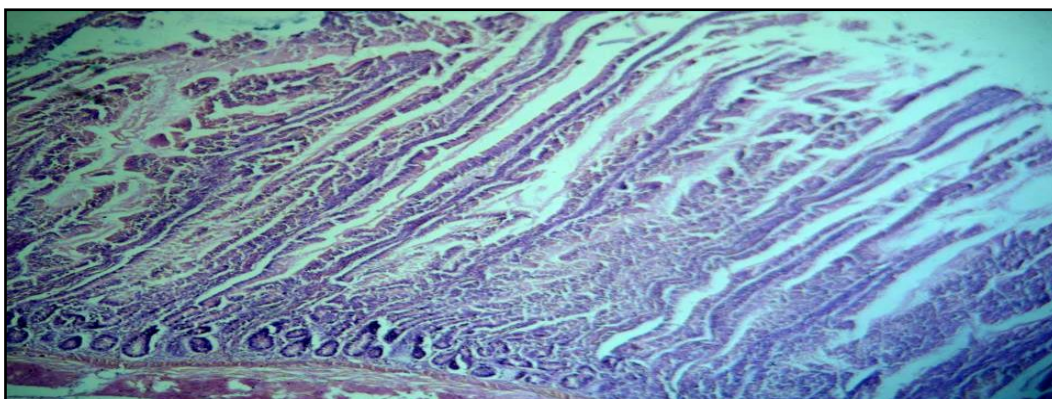


Image (4): the image of the digestive tract of infected chickens describes the damage of 10x.

DISCUSSION

Hematological and biochemical analyses are essential to monitor the health status of poultry in general and Broilers in particular, although rarely offer sufficient information to outline an etiologic diagnosis. In many species of mammals and birds, clinical and laboratory diagnosis is based largely on the results of hematological and biochemical investigations^[12].

The pattern of blood parameters for infection in chickens are different from the pattern observed in non-infection- chickens and suggested that this was due to the circadian variation in plasma volume, or to activity^[17]. Activity is probably not responsible for the pattern observed in the present study, as the local chickens remain active from morning till about 1800 hr, after they start to prepare to roost^[13].

This variation may be related to the increased metabolic activity needed to meet the energy demands for both maintenance and growth under relatively extreme stressful conditions^[14].

The decrease in Na^+ concentration might be related to concurrent loss of Na^+ and water due to loss of water from the body that causes decreased extracellular fluid volume^[15].

Variation in creatinine reflects degree of muscular activity. The significant variation observed in serum creatinine in this study, as the local chicken engages in marked muscular activity throughout the day^[18]. Three of the four serum enzymes measured in the present study, exhibited robust^[16].

The emergence of inflammation and bloating to the presence and concentration of large numbers of tapeworms and round worms in the intestines as well as the presence of nodules with a rough texture on the walls of the interior of the gut, as well as hyperplasia of epithelial cells increases the size of the intestines as well as infiltration of inflammatory cells in the intestinal walls adds to the increase in size, which leads to pressure on the walls of the intestines and thus get inflammation and swelling in the walls of the intestine^[20]. The occurrence of inflammation and the destruction and alienation of villi in places parasite adhesion to the intestinal wall^[21].

The emergence of pathological lesions in the intestines accompanied occurrence of bloody diarrhea due to erosion and the migration of parasite in the intestinal wall and adhesion layers of the intestine, making it easy movement and access to the deep layers of the intestine, the adhesion of parasites in the gut leads to erosions in the epithelial cells of the gut^[8].

Parasite regarded as a foreign body needs to be defended by the body seen in the form of infiltration of defensive cells. Inflammatory cells, especially acidic Eosinophils. That occurrence of degeneration in the current study is consistent with what has been recorded, in the intestines of infected chickens parasite. Interpreted occurrence of degeneration caused by the presence^[19].

Parasite in the intestine leads to the disintegration of the villi Where the exits, and devoid of any erosion of the original landmarks epithelial cells lining the intestinal villi and glands show^[20].

REFERENCES

- [1] Ahmad, T., and M. Sarwar. 2006. Dietary electrolyte balance: Implications in heat stressed broilers. *World's Poult. Sci. J.* 63:638–653.
- [2] Anderson RC (2000). *Nematode Parasites of Vertebrates. Their Development and Transmission*, 2nd ed. CAB International, Wallingford, Oxon, UK, pp. 265,290-299. ISBN 0-85199-421-0
- [3] Borges, S. A., A. V. Fischer da Silva, A. Majorka, D. M. Hooge, and K. R. Cummings. 2004. Physiological responses of broiler chickens to heat stress and dietary electrolyte balance (sodium plus potassium minus chloride, milliequivalents per kilogram). *Poult. Sci.* 83:1551–1558.
- [4] Griffiths HJ (1978). *A Handbook of Veterinary Parasitology: Domestic Animals of North America*. University of Minnesota Press, Minneapolis, Minnesota, USA, pp. 46-47.
- [5] Helminthiasis Introduction. *The Merck Veterinary Manual*. 2006. Archived from the original on 22 June 2007. Retrieved 2007-07-01.
- [6] Jacobs RD, Hogsette JA, Butcher JD (2003). *Nematode parasites of poultry (and where to find them)*. The Institute of Food and Agricultural Sciences (IFAS) series PS18, University of Florida, USA, pp. 1-3.
- [7] Lalchandama K (2010). "On the structure of *Ascaridiagalli*, the roundworm of domestic fowl" (PDF). *Science Vision* 10 (1): 20–30.
- [8] Olkowski, A. A., T. Duke, and C. Wojnarowicz. 2005. The aetiology of hypoxaemia in chickens selected for rapid growth. *Comp. Biochem. Physiol. A* 141:122–131.
- [9] Puvadolpirod, S., and J. P. Thaxton. 2000d. Model of physiological stress in chickens. 4. Digestion and metabolism. *Poult. Sci.* 79:383–390
- [10] Ramadan, HH; Znada, NYA (1992). "Morphology and life history of *Ascaridiagalli* in the domestic fowl that are raised in Jeddah" (PDF). *J.K.A.U. Sci.* 4: 87–99. doi:10.4197/sci.4-1.9.
- [11] Yamaguti, S.(1961). *Systema Helminthum*. 3. The nematodes of vertebrates. Interscience Publishers, New York and London, pp. 1261.
- [12] CLARK, P., W. BOARDMAN, S. RAIDAL, 2009, *Atlas of Clinical Avian Hematology*. Wiley-Blackwell, Chichester, West Sussex, UK.
- [13] FILIPOVIC, N., Z. STOJEVIC, S. MILINKOVIC-TUR, B.B. LJUBIC, M. ZDELAR-TUK, 2007, Changes in concentration and fractions of blood serum proteins of chickens during fattening. *Vet. Arhiv.*, 77, 319-326.
- [14] FIȚ, N., F. CHIRILA, G. NADAS, S. RĂPUNTEAN, L. OGNEAN, S. TRÎNCĂ, COSMINA CUC (BOUARI), 2012a, Haematological biochemical and microbiological studies at pigeons treated with a product based on metronidazole, oxytetracycline, furazolidone and bismuth subnitrate. *Bulletin UASVM, Veterinary Medicine*, 69 (1-2): 120-127.
- [15] FIȚ, N., F. CHIRILA, G. NADAS, L. OGNEAN, S. TRÎNCĂ, COSMINA CUC (BOUARI), 2012b, Haematological, biochemical and microbiological studies on sheep treated with 10% erythromycin solution. *Lucrări Științifice – vol 55 seria Medicină Veterinară*: 128-136.
- [16] HARR, K.E., 2006, Diagnostic value of biochemistry. În: *Harrison si Lightfoot Clinical Avian Medicine*, 667-685.
- [17] OGNEAN, L., VIORICA CHIURCIU, CRISTINA CERNEA, S. TRÎNCĂ, R. OROIAN, 2011b, The evaluation of therapeutic doses of erythromycin on the main hematological parameters of broiler chickens. *Bulletin UASVM, Veterinary Medicine* 68(1), 277-283.
- [18] WU., A., 2006, *Tietz Clinical Guide to Laboratory Tests*, 4th ed., Saunders Elsevier, St. Louis.
- [19] Gridley, M.F. 1960. *Manual of histologic and special staining technique*. MacGraw-Hill Book Company, 28-29, 82-83.
- [20] Hassouna, E.M.A. 2001. Some anatomical and morphometrical studies on the intestinal tract of chicken, duck, goose, turkey, pigeon, dove, quail, sparrow, heron, jackdaw, hoopoe, kestrel and owl. *Assiut Veterinary Medical Journal*. 44: 47-78.
- [21] Verdal, H. de, Mignon-Grasteau, S., Jeulin, C., Bihan-Duval, E. Le, Leconte, M., Mallet, S., Martin, C. and Narcy, A. 2010. Digestive tract measurements and histological adaptation in broiler lines divergently selected for digestive efficiency. *Poultry Science*. 89: 1955-1961.

- [22] Sokal RR, Rohlf FJ (1995) Biometry. W.H. Freeman & Co., New York Sugawara N, Lai YR, Arizono K, Ariyoshi T (1996) Biliary excretion of exogenous cadmium, and endogenous copper and zinc in the Eisai hyperbilirubinuric (EHB) rat with a near absence of biliary glutathione. Toxicology 112:87–94